OPEN

Case Report of Cryo Nerve Block in a Patient Undergoing Full Sternotomy: A Novel Approach to Pain Control in Cardiac Surgery

David J. Caparrelli, MD, FACS

Downloaded from http://journals.lww.com/aacr by BhDMf5ePHKav1zEoum1tQfN4a+kJLhEZgbsIHo4XMi0hCywCX1AWnYQp/IlQrHD3i3D0OdRyi7TvSFl4Cf3VC1y0abggQZXdtwnfKZBYtws= on 04/20/2023

We present the case of a 65-year-old man undergoing open-heart surgery through a full sternotomy with the use of bilateral intercostal cryo nerve block (cryoNB) as adjunctive therapy for postoperative analgesia. CryoNB has been previously demonstrated as safe and effective for pain control in thoracotomy procedures as well as bilaterally in adolescent patients with pectus excavatum undergoing Nuss procedure. Herein, we describe for the first time, the cryoNB procedure for postoperative pain management in a patient undergoing full sternotomy. (A&A Practice. 2023;17:e01654.)

GLOSSARY

AVR = aortic valve replacement; **CryoNB** = cryo nerve block; **CTA** = computed tomography angiography; **ESP** = erector spinae plane; **HIPAA** = Health Insurance Portability and Accountability Act; **ICU** = intensive care unit; **MME** = morphine milligram equivalent; **ORAE** = opioid-related adverse event; **POD** = postoperative day

Postoperative pain after cardiac and thoracic surgery plays a significant role in patient recovery. In thoracotomy and full sternotomy patients, severe postoperative pain can result in hypoventilation, hypoxia, pulmonary infections, and respiratory failure. While opioids have been the mainstay of postoperative pain management, the opioid epidemic has led to the implementation of multimodal nonopioid drug regimens and regional analgesia strategies. From this perspective, impressive improvement in postoperative pain in postthoracotomy patients has been observed following intercostal cryo nerve block (cryoNB). Herein, we present the case of a patient treated with cryoNB undergoing full sternotomy. The patient has provided written Health Insurance Portability and Accountability Act (HIPAA) authorization to publish this case report.

CASE DESCRIPTION

A 65-year-old man was referred to cardiac surgery for consideration of aortic valve replacement (AVR) for mixed moderate aortic stenosis and severe aortic insufficiency. The patient had a bicuspid aortic valve and normal coronary arteries. He underwent preoperative computed tomography angiography (CTA) that demonstrated a 5.6 × 4.5 × 5.4 cm mediastinal mass that was subsequently biopsy proven to be thymoma. After discussions with the thoracic oncologist, it was determined that he was an ideal open-surgical candidate. The patient was scheduled for thymoma resection and surgical AVR through a full sternotomy. Furthermore, he consented to bilateral cryoNB using the cryoSPHERE (AtriCure, Inc) cryoablation probe in an on-label, yet novel use of the device to ameliorate postoperative pain. This procedure and the intercostal nerve pathways that are ablated have been previously described in other surgical procedures.[1–4]

After the patient was induced with general endotracheal intubation, he was prepped in the usual standard fashion. A median sternotomy was made. Care was taken to resect the mediastinal mass en bloc to preserve the margins. The mass did not erode into the phrenic nerve, pericardium, or chest wall. The diagnosis of thymoma with clear margins was confirmed by frozen section.

We then turned our attention to the cryoNB (Figures 1–3). The sternal retractor was removed, and the mammary retractor placed to expose the left pleural space. The pleura was opened to expose the left thoracic cavity. Wet lap pads were placed to push the lung posteriorly to better expose the anterolateral chest wall. Then, 6 cm from the midline incision the pleura along the chest wall was incised with electrocautery from T1-T6. This provided better access to the intercostal space when applying the cryoablation probe under the rib, compressing the neurovascular bundle. Each nerve was cryoablated for 2 minutes. After the ablations on the left were completed, we performed the procedure in an identical fashion on the right. On completing the right-sided ablations, the conduct of the surgical AVR was performed per standard protocol, including sternal closure with double sternal wires and 2 SternaLock XP (Zimmer Biomet) plate-cable constructs. The patient was transported to the intensive care unit (ICU) in stable condition. The entire

From the Division of Cardiovascular and Thoracic Surgery, The New England Heart and Vascular Institute, Manchester, New Hampshire.

Accepted for publication November 14, 2022.

Funding: None.

Conflicts of Interest: See Disclosures at the end of the article.

Supplemental digital content is available for this article. Direct URL citations are provided in the HTML and PDF versions of this article on the journal's website (www.cases-anesthesia-analgesia.org).

Address correspondence to David J. Caparrelli, MD, FACS, New England Heart and Vascular Institute, 110 McGregor St, Manchester, NH 03012. Address e-mail to david.caparrelli@cmc-nh.org.

Copyright © 2023 The Author(s). Published by Wolters Kluwer Health, Inc. on behalf of the International Anesthesia Research Society. This is an open-access article distributed under the terms of the Creative Commons Attribution-Non Commercial-No Derivatives License 4.0 (CCBY-NC-ND), where it is permissible to download and share the work provided it is properly cited. The work cannot be changed in any way or used commercially without permission from the journal.

DOI: 10.1213/XAA.0000000000001654

Downloaded from http://journals.lww.com/aacr by BhDMf5ePHKav1zEoum1tQfN4a+kJLhEZgbsIHo4XMi0hCywCX1AWnYQp/IlQrHD3i3D0OdRyi7TvSFl4Cf3VC1y0abggQZXdtwnfKZBYtws= on 04/20/2023

Figure 1. Positioning of cryoprobe in the intercostal space (right side).

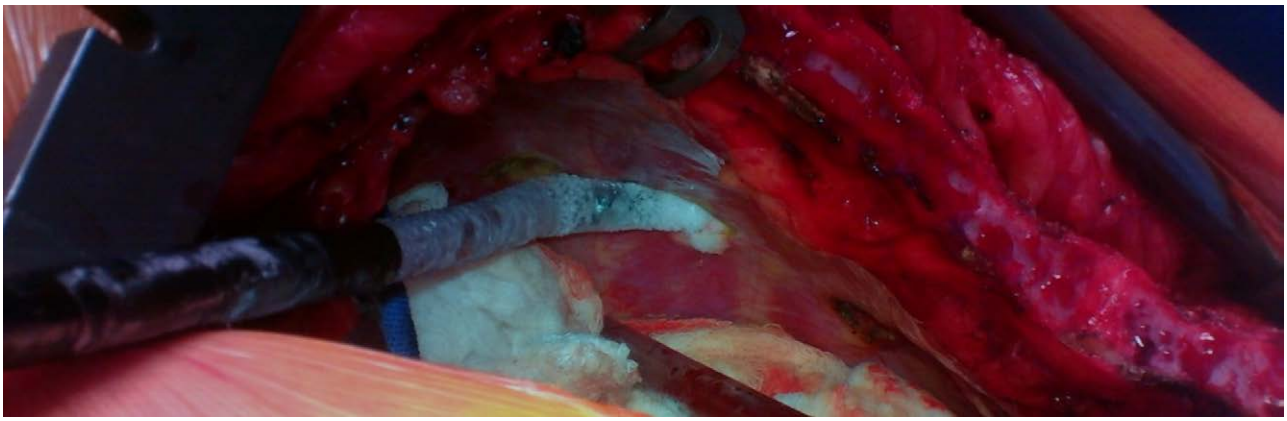

Figure 2. Cryoablation of the intercostal nerve.

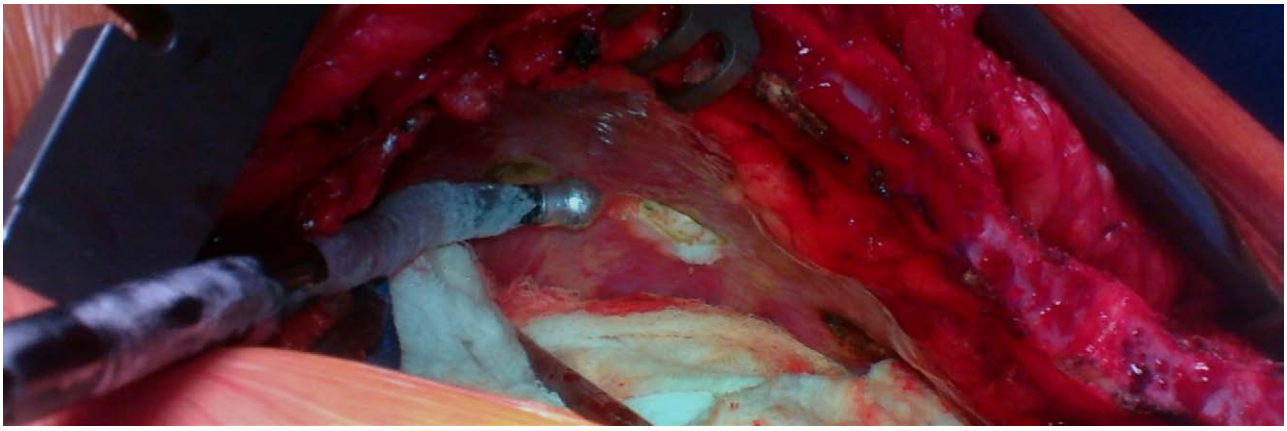

Figure 3. Active defrost and safe removal from tissue.

operation took 2 hours 54 minutes with approximately 35 minutes dedicated to cryoNB.

The patient arrived at the ICU at 11:30 and was extubated at 15:00 (3 hr 30 min). His oxygen saturation was 100% on room air by 16:00. The patient received 50 µg of fentanyl (12.5 morphine milligram equivalents [MMEs]) and 2 doses of 1000 mg of intravenous acetaminophen on the night of surgery. The patient received a total of 25 mg of oral oxycodone (37.5 MME) in 3 divided doses (10 mg night of surgery, 10 mg postoperative day [POD] 1, and 5 mg POD 2) over the course of his hospital stay. These medications were administered as part of our standard postoperative order set. The patient's average pain score (0–10) was 0.54 with a low score of 0 and a high score of 8 (22 nursing assessments during 4 PODs). Chest tubes demonstrated minimal output and were discontinued on POD 1. He described a feeling of numbness from the sternal notch superiorly to the xiphoid inferiorly and laterally to the midclavicular line. After POD 2, the patient received no pain medication or acetaminophen. The patient was

discharged home on POD 4 taking acetaminophen on an as only needed basis.

The patient returned to clinic at 1 month postoperatively. His sternal incision was well healed, and the sternum was stable. He reported no use of any pain medication other than acetaminophen and was enrolled in Cardiac Rehab. Sensation at the incision site had begun to return with no pain, and by patient report, his sensation was completely normal at 6 months. He is now over 1 year from his surgery with no complaints and no adverse sequelae.

DISCUSSION

Herein, we describe the first reported case of bilateral intercostal cryoNB in a patient undergoing open-heart surgery through a full sternotomy. This adjunctive procedure represents an on-label use of the cryoSPHERE ablation probe applied to a subset of patients not previously described. Compelling evidence exists that cryoNB is safe and effective for pain control in thoracotomy procedures (both thoracic and minimally invasive cardiac) as well as bilaterally in adolescent patients undergoing Nuss procedure.[1,5–7] While the approach to the intercostal nerves is different (unilateral for thoracic patients versus bilateral and extrathoracic for Nuss patients versus intrathoracic), the principles remain the same. Based on dermatomal maps, T1-T6 covers the sternal notch to the xiphoid encompassing the entire length of a standard median sternotomy incision.

While there are several regional techniques that have been used for pain control after cardiac surgery including bilateral erector spinae plane (ESP) blocks, paravertebral blocks, thoracic epidural, pecto-intercostal fascial plane blocks, intrathecal opioids, as well as intercostal nerve blocks with liposomal bupivacaine, these address immediate postoperative pain only. As intercostal nerves grow back after cryoablation at a rate of approximately 1 mm per day, cryoNB 6 cm from the sternal incision provides lasting pain control for up to 2 months. Despite sporadic use of the above-mentioned techniques for immediate postoperative pain, the use of opioids has been a mainstay of postoperative pain management (both inpatient and outpatient) in cardiac surgery for decades.

Opioid-related adverse events (ORAEs) associated with the side effects of opioids include sedation, respiratory depression, nausea, vomiting, ileus, tolerance, and physical dependence.[8] After cardiac surgery, patients prescribed high doses of opioids are at higher risk of developing new, persistent use, and opioid dependence.[9,10] Multimodal opioid-sparing approaches and regional analgesia in cardiac surgery are recommended[11,12] but have been slow to implementation.[12,13] Studies have suggested that intercostal cryoNB can be effective in managing pain in a multimodal setting, with potential to reduce opioid consumption.[5–7]

Potential complications related to cryoablation include neuroma formation, hyperesthesia, and poor wound healing. While previously described using other techniques, these complications have not been reported using cryoablation in the referenced publications. Moreover, Horner's syndrome related to the sympathetic chain disruption is a potential complication when the cryoprobe is applied posteriorly near the spine; however, as we are anterior at T1, this is not herein expected. Furthermore, there have been anecdotal reports of abdominal wall muscle laxity (that resolves) when the intercostal nerves below T9 are cryoablated. As we are not performing cryoNB below T6, we do not anticipate this complication in cardiac surgery patients. Finally, while pneumothorax is a potential complication associated with closed chest approaches to regional anesthesia, patients undergoing open-heart surgery routinely have chest tubes placed intraoperatively negating this as a possible complication. Pleural adhesions particularly from previous thoracic surgery could make this procedure more challenging but not impossible.

Excluding the intravenous 50 µg (12.5 MME) fentanyl dose administered on arrival to the ICU while the patient was still intubated and sedated, the total dose of 25 mg of oxycodone (37.5 MME) administered on an as needed basis, during the patient's entire hospital stay is very low compared to cardiac surgery patients treated with standard oral pain control regimens and is comparable to recently reported opioid consumption in patients undergoing cryoNB during unilateral thoracic surgical procedures that are far less invasive than median sternotomy.[14] After discharge, the patient used only Tylenol sporadically and described slow normalization of sensation in the region of treatment over several months.

While this procedure does add time and expense to the case, 35 minutes in the context of a 2-hour 54-minute cardiac surgery do not represent a substantial amount of time. Moreover, this procedure can be performed at the beginning of the cardiac surgery during which time the greater saphenous vein is often simultaneously being harvested for bypass. Further investigation weighing operative time and device-related costs against potential for decreased length of stay and the long-term savings from prevention of chronic pain and opioid dependence will need to be thoroughly investigated, as has been done using cryoNB in other surgical procedures.[15]

In this case report, bilateral intercostal cryoNB was effectively used to ameliorate pain in a patient undergoing open-heart surgery through a full sternotomy. The patient required minimal opioid analgesia as an inpatient, fully recovered without incident, and has returned to normal activity without limitation.

DISCLOSURES

Name: David J. Caparrelli, MD, FACS.
Contribution: The author contributed to this manuscript by writing it in its entirety.
Conflicts of Interest: D. J. Caparrelli is a consultant for AtriCure, Inc.
This manuscript was handled by: Kent H. Rehfeldt, MD.

REFERENCES

1. Lau WC, Shannon FL, Bolling SF, et al. Intercostal cryo nerve block in minimally invasive cardiac surgery: the prospective randomized FROST trial. *Pain Ther.* 2021;10:1579–1592.
2. Patel VH, Mora R, Padilla BE. Thoracoscopic intercostal nerve cryoablation during the Nuss procedure. *Videoscopy.* 2019;29:5.
3. Moorjani N, Zhao F, Tian Y, Liang C, Kaluba J, Maiwand MO. Effects of cryoanalgesia on post-thoracotomy pain and on the structure of intercostal nerves: a human prospective randomized trial and a histological study. *Eur J Cardiothorac Surg.* 2001;20:502–507.
4. Vossler JD, Zhao FZ. Intercostal nerve cryoablation for control of traumatic rib fracture pain: a case report. *Trauma Case Rep.* 2019;23:100229.

Downloaded from http://journals.lww.com/aacr by BhDMf5ePHKav1zEoum1tQfN4a+kJLhEZgbsIHo4XMi0hCywCX1AWnYQp/IlQrHD3i3D0OdRyi7TvSFl4Cf3VC1y0abggQZXdtwnfKZBYtws= on 04/20/2023

5. Keller BA, Kabagambe SK, Becker JC, et al. Intercostal nerve cryoablation versus thoracic epidural catheters for postoperative analgesia following pectus excavatum repair: preliminary outcomes in twenty-six cryoablation patients. *J Pediatr Surg.* 2016;51:2033–2038.
6. Zhao F, Vossler JD, Kaye A. A multi-institution case series of intercostal nerve cryoablation for pain control when used in conjunction with surgical stabilization of rib fractures. *J Cardiothorac Trauma.* 2019;4:28–34.
7. Cha PI, Min JG, Patil A, Choi J, Kothary NN, Forrester JD. Efficacy of intercostal cryoneurolysis as an analgesic adjunct for chest wall pain after surgery or trauma: systematic review. *Trauma Surg Acute Care Open.* 2021;6:e000690.
8. Benyamin R, Trescot AM, Datta S, et al. Opioid complications and side effects. *Pain Physician.* 2008;11:S105–S120.
9. Brown JK, Singh K, Dumitru R, Chan E, Kim MP. The benefits of enhanced recovery after surgery programs and their application in cardiothoracic surgery. *Methodist DeBakey Cardiovasc J.* 2018;14:77–88.
10. Clement KC, Canner JK, Whitman GJR, Lawton JS, Grant MC, Sussman MS. New persistent opioid use after aortic and mitral valve surgery in commercially insured patients. *Ann Thorac Surg.* 2020;110:829–835.
11. Engelman DT, Ben Ali W, Williams JB, et al. Guidelines for perioperative care in cardiac surgery. *JAMA Surg.* 2019;154:755–766.
12. Bignami E, Castella A, Pota V, et al. Perioperative pain management in cardiac surgery: a systematic review. *Minerva Anestesiol.* 2018;84:488–503.
13. Gregory AJ, Grant MC, Manning MW, et al. Enhanced recovery after cardiac surgery (ERAS Cardiac) recommendations: an important first step—but there is much work to be done. *J Cardiothorac Vasc Anesth.* 2020;34:39–47.
14. O'Connor LA, Dua A, Orhurhu V, Hoepp LM, Quinn CC. Opioid requirements after intercostal cryoanlagesia in thoracic surgery. *J Surg Res.* 2022;274:232–241.
15. Graves CE, Moyer J, Zobel MJ, et al. Intraoperative intercostal nerve cryoablation during the Nuss procedure reduces length of stay and opioid requirement: a randomized clinical trial. *J Pediatr Surg.* 2019;54:2250–2256.

Downloaded from http://journals.lww.com/aacr by BhDMf5ePHKav1zEoum1tQfN4a+kJLhEZgbsIHo4XMi0hCywCX1AWnYQp/IlQrHD3i3D0OdRyi7TvSFl4Cf3VC1y0abggQZXdtwnfKZBYtws= on 04/20/2023